

Adult intussusception: Case series

Garg P, Garg G, Verma S, Mittal S, Rathee VS, Narang A, Aggarwal S

ABSTRACT

Adult intussusception occurs infrequently and differs from childhood intussusception in its presentation, aetiology and treatment. Diagnosis can be delayed because of its intermittent and non-specific symptoms for a considerable period. Most cases are diagnosed at emergency laparotomy. However, with frequent use of CT scan in the evaluation of patients with acute abdomen in recent times, the conditions are diagnosed more readily and reliably. Treatment entails simple bowel resection in most cases. However, innovative techniques may be required in some cases of gastroduodenal and coloanal intussusceptions.

Key words: adult intussusceptions, intestinal obstruction, laparotomy, acute abdomen

INTRODUCTION

Intussusception is defined as telescoping of one segment of the gastrointestinal tract into an adjacent one.¹ It is leading cause of intestinal obstruction in children and ranks second only to appendicitis.^{2,3} However in adults, intussusception is rare accounting only 0.1% of all adult hospital admissions^{4,5,6} and 5%-16% of all intussusceptions.^{4,7,8} In adults, about 90% of intussusceptions occur in the small or large bowel, remaining 10% involve the stomach or surgically created stomas.⁹⁻¹³ In contrast to childhood intussusceptions which is idiopathic in 90% of cases, adult intussusceptions has a demonstrable cause in over 90% of cases.²⁻⁸

Adult intussusception may present as a chronic indolent type of obstruction or as an acute abdomen.^{5,10} In children 16% of intussusceptions occur in the postoperative period, accounting of 10-15% of all childhood post-operative obstructions.³ In adults, however, we do not have many reports of intussusceptions as a cause of postoperative obstruction. There is mention of a single case of postoperative (secondary) ileocolic intussusceptions, thought to be due to anastomotic lumen disparity following right hemicolectomy for ileocecal tuberculosis.¹⁴

The diagnosis in adults is usually made at laparotomy, as most patients present as an emergency with intestinal obstruction. In non-emergency patients the diagnosis can be challenging as symptoms include intermittent

abdominal pain that often settles comparatively quickly; clinical examination and investigations are often negative; and these patients frequently are labeled as having irritable bowel syndrome.

Treatment entails simple bowel resection in most cases. Reduction of the intussusception before resection is controversial, but there is a shift against this, especially in colonic cases. Surgical treatment can be difficult in gastroduodenal and coloanal intussusceptions, sometimes requiring innovative techniques. This case series presents the diagnosis and management of three cases of adult intussusceptions.

CASE 1

A 37 years old woman was admitted with complaints of pain epigastrium and left hypochondrium with intermittent vomiting for 15 days. Pain was dull aching radiating to back. She was managed conservatively and symptoms improved but recurred several times. General physical examination and systemic examination was normal. Locally, a diffuse, non-tender and mobile lump of size 6 cm x 5cm with smooth surface and ill-defined margin was palpated. All biochemical investigations were normal.

Ultrasonography revealed a mass of size 51x31 mm diagnosed to be an intussusceptions in left paraumbilical region with thickening of mesenteric lymph nodes. Subsequent CT scan endorsed clinical and ultrasonographic diagnosis.

On laparotomy, segment of around 10-15cms of transverse colon was found telescoping into transverse colon and a growth of 5cm x 5cm size was present at lead point. Transverse colon containing the growth was resected and primary anastomosis was done. Growth was diagnosed to be a tubule-villous adenoma on histopathology.

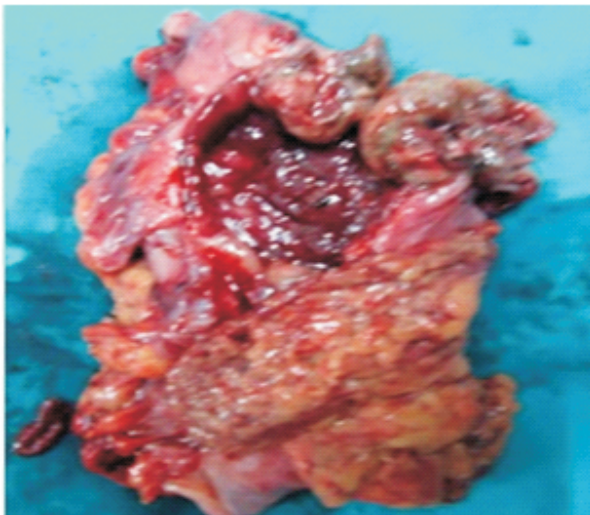


Figure 1. Colocolic intussusceptions secondary to tubule-villous adenoma in 37 years old woman

Case 2

A 27 years man was admitted with complaint of pain abdomen and constipation for two days and vomiting for one day. Pain was sudden, dull and intermittent around the umbilical area later spread to bilateral iliac fossa, and was associated with vomiting. On palpation, a non-tender, firm mass was present in right iliac fossa. Ultrasonography revealed telescoping of gut loop along with mesenteric lymph nodes.

On laparotomy a segment of ileum intussuscepting into caecum reaching up to hepatic flexure was found. On gentle pulling intussusceptum came out and it showed gangrenous changes. No other pathology was found. Gangrenous segment was excised and ileostomy was done with closure of distal end. Pathology of resected segment showed gangrenous change with transmural ischemic necrosis.

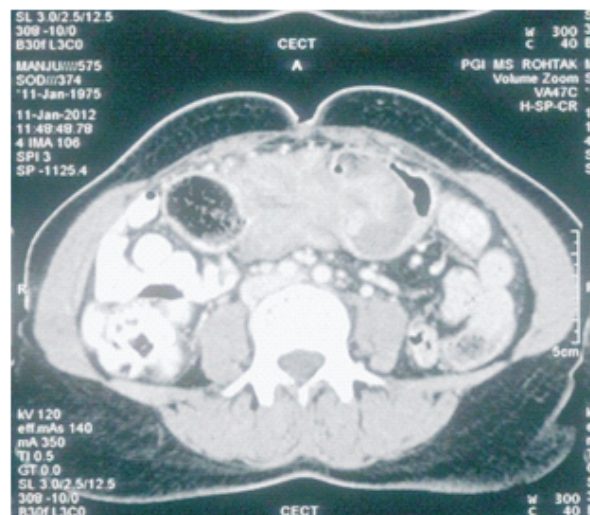


Figure 2. Abdominal computed tomogram showing a classic target lesion, suggesting colo-colic intussusception.

Case 3

A 32 years old man presented with complaint of pain upper abdomen for ten days; bilious vomiting with non passage of flatus and stool for seven days. Pain was sudden, dull, intermittent in epigastric regions with radiation. On palpation, a non-tender, firm mass was present in left hypochondrium.

On laparotomy, a segment of small bowel with proximal segment telescoping into distal segment was found 3 feet distal to duodeno-jejunal junction, with a growth at lead point. Whole of the segment was excised and end-to-end anastomosis done.

Histopathology showed features of non-Hodgkin's lymphoma. One cut ends was involved by the tumour while other was free. Leukocyte common antigen (CD 45) was positive. CD 117 and cytokeratine was negative.

In all the three cases post operative recovery was uneventful.

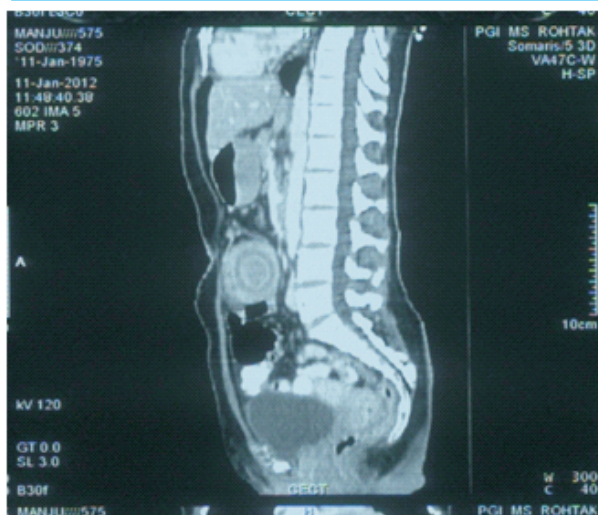

Figure 3. Abdominal computed tomogram showing a classic target lesion, suggesting colo-colic intussusception

DISCUSSION

The single most common site for adult intussusception is the small bowel.¹⁵ Colo-anal intussusceptions are rare and usually occur in the setting of a benign or malignant tumour, with 50% attributable to a malignant lesion.¹⁶ It is important to differentiate this from rectal prolapse, which can be done by a careful clinical examination. Gastro-duodenal intussusception, the least frequent of all, is usually caused by the prolapse of a benign gastric tumour into the duodenum, with subsequent invagination of a portion of the stomach wall.¹⁷

As was in case-3, the lead points for the intussusceptions are attributable to benign, malignant, or idiopathic causes.¹⁵ Although all our three patients had a benign pathology, primary or secondary malignant lesions may account for 6% to 30% of all cases. In a review by Felix et al,¹⁸ tumour related intussusceptions were noted in 63% of cases.

Intussusception has also been noted in patients with tropical sprue/celiac disease, abdominal trauma, and in postoperative period. In addition, this condition has been noted increasingly among patients with AIDS related gut disease.¹⁹⁻²² Idiopathic intussusception in the small bowel accounts for 8% to 20% of all cases.¹⁸⁻²³

The presenting symptoms in adult patients with

intussusceptions are non-specific and often long standing. Pain is the commonest symptom, being present in 71% to 90% of patients, with vomiting and bleeding from the rectum as the next most common symptoms.²⁴ The most important characteristic of pain is its periodic, intermittent nature, which makes the diagnosis elusive and accounts for the delay in making the diagnosis, with only half the cases being diagnosed before operation.²⁴ Abdominal mass is noted in 24% to 42% of cases.^{15,23}

Computed tomography seems to be the most reliable investigation in making a preoperative diagnosis, especially in those patients with non-specific abdominal pain. Its accuracy has been confirmed at operation by some studies. In our study, computed tomography was carried out in one patient and it was diagnostic in this patient. Ultrasonography aided diagnosis was made in one case. Other investigations like barium enema, colonoscopy or flexible sigmoidoscopy are also in use.²³

Adult intussusception warrants laparotomy rather than attempts at hydrostatic reduction in view of the high incidence of underlying abnormality.^{23,25} Controversy remains as to whether reduction of the intussuscepting lesion should be attempted at operation. Early reports advocated reducing the intussusception before resection. The perceived disadvantage of this is that malignant cells may be disseminated during the process despite no clear evidence on this issue. On the other hand, the advantages of reducing the intussusception especially when the small bowel is involved, is the preservation of considerable lengths of bowel and thereby prevent development of short bowel syndrome.

Begos et al,²⁵ suggested resection without attempting reduction when the bowel is inflamed, ischaemic, or friable and in obvious colo-colic intussusception (given the high likelihood of malignancy). In all other cases reduction should always be attempted initially. However, Azar et al,²³ suggested that surgical resection without reduction is the preferred treatment in adults, as

almost 50% of both colonic and enteric intussusceptions are associated with malignancy. Simple reduction is however acceptable in post-traumatic and idiopathic intussusceptions where no pathological cause is usually present in the bowel.

CONCLUSION

Intussusception in adults is an infrequent problem. Its diagnosis can be difficult as symptoms are often non-specific and episodic thus attracts to have a high index of suspicion. The most useful investigation is abdominal computed tomography. Treatment requires resection without attempted reduction in colonic lesions; and in small bowel cases where the bowel is non-viable or in suspected malignancy. With gastroduodenal and coloanal intussusceptions the surgical technique may need modification according to the situation and can be challenging.

AUTHOR NOTE

Pradeep Garg, Senior Professor,
Contact- +91 9416122922,
E mail: drpradeepgarg@rediffmail.com

(Corresponding author)

Gulshan Garg, Senior Resident
Surender Verma, Senior Resident
Sachin Mittal, Resident
Vazir Singh Rathee, Assistant Professor
Amit Narang, Resident
Sourabh Aggarwal, Resident
Department of Surgery, Pt. B.D.Sharma Post
Graduate Institute of Medical Sciences, Rohtak,
Haryana, India. PIN- 124001.

REFERENCES

1. Gayer G, Apter S, Hofmann C, Nass S, Amitai M, Zissin R, Hertz M. Intussusception in adults: CT diagnosis. *Clin Radiol*. 1998 Jan;53(1):53-7.
2. Coran AG. Intussusception in adults. *Am J Surg*. 1969 May;117(5):735-8.
3. Raffensperger JG, Baker RJ. Postoperative intestinal obstruction in children. *Arch Surg*. 1967 Apr;94(4):450-9.
4. Donhauser JL, Kelly EC. Intussusception in the adult. *Am J Surg*. 1950 May;79(5):673-7.
5. Deterling RA Jr, O'Mallery RD, Knox W. Intussusception in the adult with emphasis on retrograde type. *AMA Arch Surg*. 1953 Dec;67(6):854-64.
6. Briggs DF, Carpathios J, Zollinger RW. Intussusception in adults. *Am J Surg*. 1961;101:109-113.
7. Brayton D, Norris WJ. Intussusceptions in adults. *Am J Surg*. 1954;88(1):32-43.
8. Colter AM, Cohen I Jr. Intussusception in Adults. *Am J Surg*. 1961;101:114-120.
9. Stubenborg WT, Thorbjarnarson B. Intussusception in adults. *Ann Surg*. 1970;172: 306-310.
10. Burmeister RW. Intussusception in the adult, an elusive case on recurrent abdominal pain. *Am J Dig Dis*. 1962;7:360-74.
11. Felix EL, Cohen MH, Bernstein AD, Schwartz JH. Adult intussusception; case report of recurrent intussusception and review of the literature. *Am J Surg*. 1976 Jun;131(6):758-61.
12. Aston SJ, Machlfeder HI. Intussusception in the adult. *Am Surg*. 1975 Sep;41(9):576-80.
13. Lou CJ. Intussusception in adults. An analysis of 92 cases. *Chin Med J (Engl)*. 1982 Apr;95(4):297-300.
14. Godara R, Garg P, Dalal S, Nityasha, Singla SL. Adult intussusception - a case series from rural India. *Trop Doct*. 2007 Oct;37(4):258-60.
15. Stubenbord WT, Thorbjarnarson B. Intussusception in adults. *Ann Surg*. 1970 Aug;172(2):306-10.
16. Nesbakken A, Haffner J. Colo-recto-anal intussusception. Case report. *Acta Chir Scand*. 1989 Mar;155(3):201-4.

17. Lin F, Setya V, Signor W. Gastroduodenal intussusception secondary to a gastric lipoma: a case report and review of the literature. *Am Surg*. 1992 Dec;58(12):772-4.
18. Felix EL, Cohen MH, Bernstein AD, Schwartz JH. Adult intussusception; case report of recurrent intussusception and review of the literature. *Am J Surg*. 1976 Jun;131(6):758-61.
19. Brooks A, Bebington BD, Lucas S, Oettle GJ. Intussusception caused by blunt abdominal trauma. *J Trauma*. 1999 Jul;47(1):156-7.
20. Eke N, Adotey JM. Postoperative intussusception, causal or casual relationships? *Int Surg*. 2000 Oct-Dec;85(4):303-8.
21. Danin JC, McCarty M, Coker R. Case report: lymphoma causing small bowel intussusception in a patient with the acquired immune deficiency syndrome. *Clin Radiol*. 1992 Nov;46(5):350-1.
22. Meyerson S, Desai TK, Polidori G, Raval MF, Ehrinpreis MN. A case of intussusception and lymphoid hyperplasia in a patient with AIDS. *Am J Gastroenterol*. 1993 Feb;88(2):303-6.
23. Azar T, Berger DL. Adult intussusception. *Ann Surg*. 1997 Aug;226(2):134-8.
24. Reijnen HA, Joosten HJ, De Boer HH. Diagnosis and treatment of adult intussusception. *Am J Surg*. 1989 Jul;158(1):25-8.
25. Begos DG, Sandor A, Modlin IM. The diagnosis and management of adult intussusception. *Am J Surg*. 1997 Feb;173(2):88-94.