

Tubercular parotitis - A possibility in parotid fistula

Garg P, Mittal M

ABSTRACT

Tuberculosis of parotid is rare, yet the possibility should strongly be considered in an Indian patient presenting with fistula after drainage of parotid abscess by a surgeon. This will obviate the need of superficial parotidectomy.

Keywords: parotid abscess, tuberculous parotitis, parotid fistula

INTRODUCTION

Primary tuberculous parotitis is a rare clinical entity. Clinical presentation as abscess or fistula leads to delay in exact diagnosis, particularly when the abscess has been drained by a qualified surgeon. We report one such case to enrich the literature and highlight the message that in India, tuberculous parotitis must be the first differential diagnosis in persistent fistula resulting from incision and drainage of parotid abscess.

CASE REPORT

A 40 year old man presented with diffuse mild swelling of left parotid with a fistula for three months. He underwent incision and drainage for a parotid abscess by a qualified surgeon three month before; since then the fistula was persisting. General physical, local and systemic examination did not reveal any contributory positive findings. Haematological parameters were within normal limits. Chest skiagram was normal. Superficial parotidectomy was performed. During surgery there were some small pockets of pus in superficial lobe. Postoperatively he did have mild serous discharge from lower end of wound (Figure 1). Histopathology of the specimen revealed central caseating necrosis with epithelioid and langerhans giant cells, suggestive of tuberculosis (Figure 2). Antitubercular treatment (four drug regime) was given and the patient has no evidence of discharge from wound now.

DISCUSSION

Tuberculosis of parotid gland is uncommon and

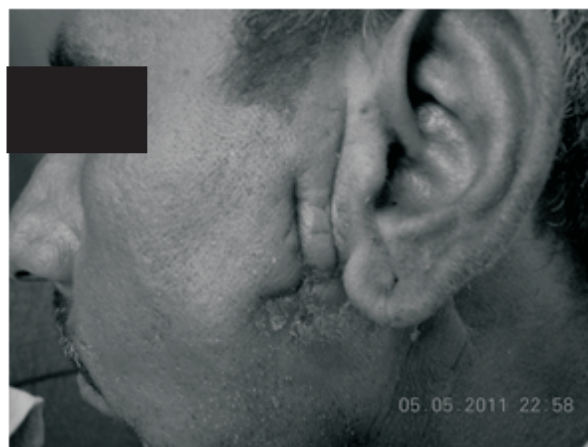


Figure 1. Post operative photograph of the patient (1 month after operation)

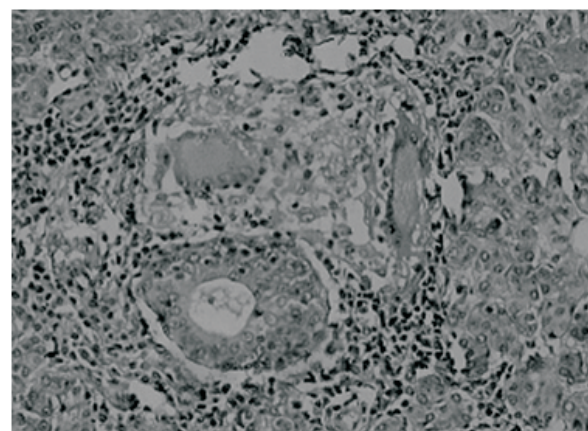


Figure 2. Histopathology of parotid gland showing features of tuberculosis.

only 100 cases have been described in literature in immunocompetent patients.¹ Another form of clinical presentation is periauricular fistula or abscess.² Atypical mycobacterium rarely infects the parotid.³

Primary tuberculosis of parotid gland presents in two forms: first as an acute inflammatory lesion mimicking sialoadenitis with abscess formation. The parotid tissue is oedematous, friable and indurated at places. Second presentation is chronic tuberculous lesion which is circumscribed. The lesion presents as gradually increasing mass over months to years with no symptoms apart from swelling. On clinical examination it is impossible to distinguish them from parotid neoplasm. The first form is a commoner presentation than the second one.

If the diagnosis is made preoperatively, parotid tuberculosis can be treated with antitubercular drugs and no surgery is required. Otherwise, full course of antitubercular therapy is to be given after

parotidectomy. Though rare, the possibility of tuberculosis should be considered as differential diagnosis in parotid fistula particularly because early diagnosis and treatment are mandatory.

AUTHOR NOTE

Pradeep Garg, Senior Professor,
Contact- +91 9416122922,
E mail: drpradeepgarg@rediffmail.com

(Corresponding author)

Sachin Mitaal, Resident
Department of Surgery, Pt. B.D.Sharma Post
Graduate Institute of Medical Sciences, Rohtak,
Haryana, India. PIN- 124001.

REFERENCES

1. Rangel AL, Coletta RD, Almeida OP, Graner E, Lucena A, Saldiva PH, Vargas PA. Parotid mycobacteriosis is frequently caused by Mycobacterium tuberculosis in advanced AIDS. *J Oral Pathol Med.* 2005 Aug;34(7):407-12.
2. Suleiman AM. Tuberculous parotitis: report of 3 cases. *Br J Oral Maxillofac Surg.* 2001 Aug;39(4):320-3.
3. Bakhshi GD, Shaikh AS, Borisa AD, Jamadar NM, Singh AG, Vora SH. Primary tuberculosis of parotid gland mimicking parotid tumor. *Bombay Hospital Journal (special issue).* 2009:14-16.