

## Rectal perforation by bamboo stick- A case report

Garg G, Garg P, Singh V, Verma S, Mittal S

### ABSTRACT

Rectal perforation by foreign body presents a management dilemma, as the type of object, the amount of force used, time from insertion and degree of local contamination may vary widely. Delay in seeking medical help and failure to provide proper history about the incident often poses difficulty at many levels. Management of these patients may be challenging, as diagnosis is often based on high degree of suspicion.

**Key words:** rectal perforation, foreign body, bamboo stick, exploratory laparotomy, peritonitis.

### INTRODUCTION

Perforation of rectum by foreign body insertion has been extensively described in the surgical literature in the form of case reports or case series. The reported incidence of rectal foreign bodies is rather rare, as it is associated with taboo and social stigma. Often it is associated with a sexual component with both genders equally vulnerable.<sup>1</sup> Some homosexuals insert foreign bodies into their rectum for pleasure. Occasionally, while moving an object back and forth, a homosexual or his partner may lose his grip and it may get sucked into the colo-rectum. Furthermore, with dilatation of the anal sphincters; the victims often resort to use larger objects to get the same level of satisfaction. The nature and type of foreign body recovered during surgery varies widely and depends on the socio-cultural and ethnic background of the victim and the availability of the suitable material.<sup>2,3,4</sup> Anal masturbation may also result in perforation; knowledge of the pelvic anatomy is no immunity.<sup>5</sup> Death resulting from rectal insertion of foreign objects is rare. Byard et al., described the case of a 56-year-old man attempting sexual stimulation via the insertion of a shoehorn into his anus, tore his rectum, did not seek medical help, and bled to death.<sup>6</sup>

A problem commonly encountered in these patients is the delay in presentation.<sup>7,8</sup> It is difficult to estimate the duration of insertion or injury because they appear in emergency departments only when they require professional help in retrieving stuck rectal objects, or when some

medical complications arise. Sometimes the foreign body may be retained for a considerable period of time before its recovery. Buzzard et al., reported the removal of a plastic vibrator from the rectum of a 65-year-old man who had had it in his rectum for 6 months and even traveled around the world with it.<sup>9</sup>

While patients may be reluctant to disclose the cause of their presentation, diagnosis can be made in the majority of cases with accurate history and confirmed with plain radiographs. It is important to rule out signs and symptoms of peritonitis. It is also essential for the emergency room physicians and general surgeons to be systematic in their approach and be familiar with a variety of extraction techniques and management of colorectal injuries resulting from the insertion or extraction of the foreign body.

### CASE REPORT

A 22 years man presented to emergency department with complaints of pain and distension abdomen. Pain started in lower part abdomen two days back, which was not relieved by medication. There was an alleged history of sexual assault three days back. As per the history, an acquaintance had forcibly introduced bamboo stick into his anal canal after a failed attempt of sodomy.

On examination patient had fever and tachycardia. The abdomen was distended, liver dullness obliterated, bowel sounds absent and tenderness

was present all over the abdomen. Chest skiagram showed subdiaphragmatic free air. Ultrasonography revealed free fluid with specks of air in peritoneal cavity. Per rectal examination revealed normal anal sphincter tone. There was a rent, palpable in the anterior rectal wall.

Exploratory laparotomy was done by lower midline incision under general anesthesia. At the junction of lower and middle third of rectum, there was an intraperitoneal rectal perforation anteriorly, of size about 3 cm, with ragged margins and pus flakes were present. (Fig.-1) Small intestine was edematous. Margins of the perforation were freshened and repair was done in single layer. Loop sigmoid colostomy was done. Post-operative period was uneventful.

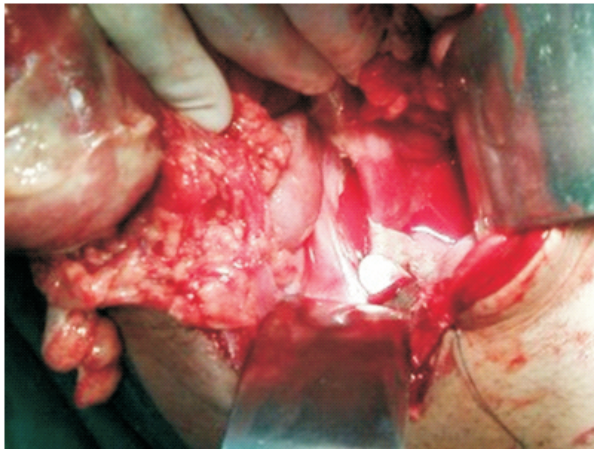


Fig 1. Showing rectal perforation.

## DISCUSSION

Although cases of anally-inserted foreign object causing problems are not common, if proper treatment is not administered in emergency situations, complications of anorectal dysfunction, fecal incontinence, perforation, peritonitis, pelvic abscess, etc. may occur. The majority of rectal foreign bodies seen in practice are a result of deliberate insertion into the anal canal.<sup>10,11</sup> These may have been inserted purposefully by the patient themselves as in anal masturbation, or by a sexual partner. These foreign bodies are usually blunt and take the shape of male genitalia.<sup>12,13</sup> Those who do it habitually over time find that due to the

increasing laxity of their rectal tone, they can insert objects of a higher caliber, that may sometimes be difficult to remove and eventually may result in injury or infection. Conversely, victims of sexual assault may present with objects of varying caliber, and these need not necessarily be of a blunt type. In the instant case, the history was suggestive of forcible insertion of a bamboo stick due to non refusal at sodomy. However, he could not justify the exact situation to corroborate with the history. We did a forensic evaluation accordingly, as the case merited a medico-legal approach.

Rectal perforations from anal penetration may typically present acutely with signs and symptoms of trauma, such as bleeding and perforation. As seen in our case, the common presenting complaints include severe guarding, rebound tenderness, and fever, and these patients may appear septic.<sup>7</sup> Therefore, physical examination should primarily focus on ruling out peritonitis. A rectal examination should be performed to assess the location of the perforation, and to determine sphincter competency. It is uncommon for the sphincter to have been injured in cases of voluntary insertion. Furthermore, if there are signs and symptoms of bowel perforation, attempts at removal should cease and surgeon should be consulted emergently as well.

Routine laboratory investigation is recommended to assess the extent of physiologic derangement resulting from perforation. An abdominal X-ray would define the nature, size and shape of the foreign body, its location, if any, and to diagnose subdiaphragmatic free air. In addition, an ultrasonography may help reveal some clues, like free fluid with specks of air in peritoneal cavity, as seen in this case.

Where there are peritoneal signs, the patient needs to be considered for surgery in the form of laparotomy. A lower midline incision is ideal. The first step is to assess the sigmoid distally to rule out transmural injury. Those with lacerations of the colon that involve less than one third to half the circumference and are fresh and not accompanied with gross peritoneal contamination can be

repaired primarily. With higher circumference injuries, a Hartmann's procedure may be needed. Diversion should also be considered in patients with delayed presentation, significant fecal contamination, signs of sepsis and hemodynamic instability. In our case, closure of perforation was done with defunctioning loop colostomy.

## CONCLUSION

This case report highlights the seriousness of rectal injuries following unusual sexual practices. Complications in such cases can be attributed to the late presentation and established faecal peritonitis. Management of these cases may be challenging, as reluctance to seek medical help and

failure to provide details about the incident often makes diagnosis difficult. A systematic approach is proposed to avoid pitfalls.

## AUTHOR NOTE

Gulshan Garg, Senior Resident

Pardeep Garg, Senior Prof,

Contact – 09416122922

**(Corresponding Author)**

Vazir Singh, Assistant Professor

Surender Verma, Senior Resident

Sachin Mittal, Junior Resident

Department of Surgery, Pt. B.D.Sharma Post Graduate Institute of Medical Sciences, Rohtak, Haryana, India. PIN- 124001.

## REFERENCES

1. Crass RA, Tranbaugh RF, Kudsk KA, et al. Colorectal foreign bodies and perforation. *Am J Surg* 1981; 142(1):85-8.
2. Singla SL, Chitkara N., Singla B., Garg P, Dhiv V. Whisky bottle in rectum. *Ind J Gastroenterology* 1996; 15(3) :113.
3. Barone JE, Sohn N, Nealon TF, Jr. Perforations and foreign bodies of the rectum: report of 28 cases. *Ann Surg.* 1976 Nov;184(5):601-4.
4. Busch DB, Starling JR. Rectal foreign bodies: case reports and a comprehensive review of the world's literature. *Surgery.* 1986; 100(3):512-9.
5. Schaupp WC. Commentary. *Am J Surg* 1981;142(1):85-8.
6. Byard RW, Eitzen DA, James R. Unusual fatal mechanisms in nonasphyxial autoerotic death. *Am J Forensic Med Pathol.* 2000; 21(1):65-8.
7. Goldberg JE, Steele SR Rectal foreign bodies. *Surg Clin North Am.* 2010;90:173–184.
8. Kurer MA, Davey C, Khan S, Chintapatla S. Colorectal foreign bodies: a systematic review. *Colorectal Dis.* 2010; 12 (9):851–861.
9. Buzzard AJ, Waxman BP. A long standing much travelled rectal foreign body. *Med J Aust* 1979; 1(13):600.
10. Lyons MF, Tsuchida AM. Foreign bodies of the gastrointestinal tract. *Med Clin North Am.* 1993; 77(5):1101–1114.
11. Moreira CA, Wongpakdee S, Gennaro AR. A foreign body (chicken bone) in the rectum causing extensive perirectal and scrotal abscess: report of a case. *Dis Colon Rectum.* 1975; 18(5):407–409.
12. Fry RD. Anorectal trauma and foreign bodies. *Surg Clin North Am.* 1994; 74(6):1491–1505.
13. Clarke DL, Buccimazza I, Anderson FA. et al. Colorectal foreign bodies. *Colorectal Dis.* 2005; 7(1):98–103.