

## Percutaneous drainage of isolated splenic abscess: Report of two cases

Kumar VR, Chikkannachari TR, Mukarji A, Kumar HRS, Belodu R

### ABSTRACT

Abscess of the spleen is a rather clinical rarity with reported mortality rate up to 47%. Widespread use of imaging methods facilitates early diagnosis and focused treatment, improving the prognosis. Surgical treatment by splenectomy is usually the first choice in such cases. We report two cases with similar presentations of fever with chills and rigor, pain left side of abdomen and having diabetes. The clinical diagnosis was aided by imaging techniques viz. X-rays, ultrasonography and CT scan. Both were treated successfully by percutaneous drainage.

**Keywords:** splenic abscess, splenectomy, percutaneous drainage, imaging techniques

### INTRODUCTION

Abscess of the spleen is a rather clinical rarity as only about 600 cases have been described so far in the international literature with reported mortality rate up to 47%.<sup>1,2</sup> Most of the patients were having recognized risk factors including conditions that compromise the immune system, such as endocarditis, diabetes mellitus, congenital or acquired immunodeficiency and immunosuppressive medications.<sup>2</sup> Clinical manifestation of splenic abscesses usually include left upper abdominal pain, fever, nausea, vomiting and anorexia in various combinations. Traditionally, the 'gold standard' treatment has been splenectomy, but recently there has been increasing use of non-operative methods. The cases presented here are rare and were managed successfully by percutaneous drainage.

### CASE DETAILS

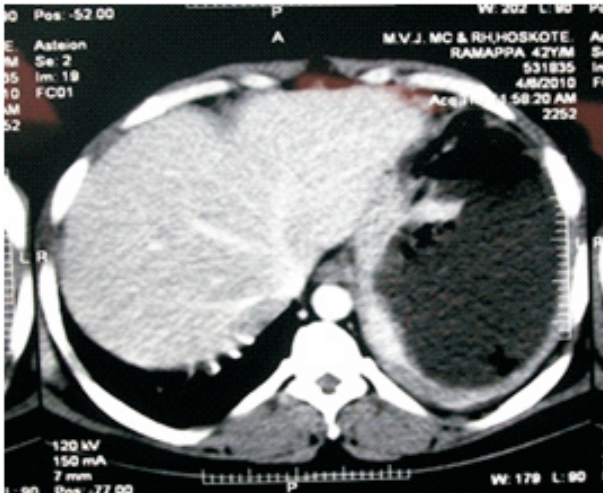
#### CASE 1

A 42 year old man presented to the Department of Emergency Medicine with complaints of intermittent fever for one month; associated with chills and rigors, and dull aching pain in the left side of abdomen with generalized weakness for the last 15 days. He was recently diagnosed with diabetes. He was treated empirically for enteric fever few days back. He had a history of trauma to the left side of the chest in an accident. Physical Examination

revealed coated tongue, pyrexia, generalized toxic features; pulse 90/min and blood pressure 110/70 mmHg. Focused abdominal examination revealed soft and scaphoid abdomen, firm and enlarged spleen palpable up to 5 cm below the left costal margin. There was no hepatomegaly or free fluid. Bowel sounds appeared normal. Total WBC count was 15000/cmm, fasting blood sugar 210 mg/dl, post prandial sugar 250 mg/dl, tests for HIV and HBsAg negative, and chest and abdominal radiograph was normal. Ultrasonography (USG) of abdomen revealed irregular hypoechoic lesion of volume of about 1000 ml indicating splenomegaly. Computed tomography abdomen demonstrated spleen measuring 15.2 x 8 x 19 cm with a volume of 1200 ml. Patient was started with broad spectrum antibiotics. A pig tail catheter of 10F was inserted under USG guidance and a continuous drainage was allowed. An amount of 2050 ml of pus was drained over a period of seven days. Pus was subjected to culture test and did not reveal any growth. Pus stopped draining on eighth day, and the patient showed improvement in his general condition.

Follow up ultrasound abdomen showed a residue of 50 ml pus. As no more pus was draining the pig tail catheter was removed on 10<sup>th</sup> day. He was kept under observation for a week and discharged with advice to continue with oral hypoglycemic agents and antibiotics. He was instructed to follow up after

a week and report back immediately if fever and abdominal pain recur. Follow up examinations revealed soft, non tender abdomen, and spleen was not palpable. Repeat ultrasound abdomen showed no residual pus.

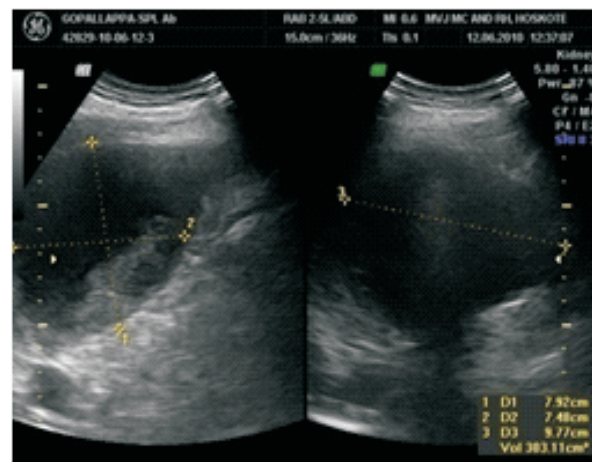


Picture 1. CT scan image showing enlarged spleen with abscess.

## CASE 2

A 58 year old man presented to Emergency Medicine Department with complaints of intermittent fever associated with chills and rigors for 15 days, cough with mucopurulent expectoration for one week and dull aching pain in the left side of abdomen since one week. He was a known diabetic and was not taking medications regularly. Focused examination revealed soft abdomen, enlarged, tender and firm spleen, extending 8 cm below the costal margin. Breath sounds was decreased on the left side with basal crepitations. Blood counts and renal function were within normal limits. Fasting blood sugar was 250 mg/dl, and post prandial blood sugar 310 mg/dl. Tests for HIV and HBsAg were negative. Abdominal radiograph was normal. Chest radiograph showed obliteration of left costophrenic angle. Ultrasounography revealed splenomegaly associated with a cystic lesion of 3.7 x 1.6 cm and 500 ml volume. CT abdomen showed a large, well defined, non-enhancing, hypodense fluid collection in spleen suggestive of splenic abscess. Patient was started on broad spectrum antibiotics. An ultrasound guided pig tail catheter 10F was inserted and a continuous drainage was allowed. An amount of 450 ml of pus was drained over a period of 5 days.

Pus culture was negative. He improved markedly and pus stopped draining on 5<sup>th</sup> day. Follow up ultrasound abdomen showed no residual pus and the catheter was removed on 5<sup>th</sup> day. Patient stayed in the hospital for another week for observation. He was discharged with oral hypoglycemic agents and antibiotics. After one week follow up, his general condition was improved; abdomen was soft, non tender, and the spleen was not palpable. Repeat ultrasound abdomen showed no residual pus.



Picture 2. Ultrasound abdomen showing splenic abscess.

## DISCUSSION

Splenic abscess is an uncommon and potentially fatal illness, with about 600 cases reported in the literature so far, and with a reported frequency of 0.05-0.7% on autopsy studies.<sup>1,2,3</sup> It occurs more frequently in the tropics, where there is a higher incidence of sickle cell anemia, with associated thrombosis of parenchymal vessels and consequent infarction. The major risk factors are intravenous drug use, human immunodeficiency virus disease, hematogenous spread, endocarditis, splenic trauma, and contiguous spread. Most infections are polymicrobial and include Staphylococcus, Streptococcus, E.coli, Proteus, Bacteroids & Fusobacterium.<sup>4</sup> The symptoms are usually nonspecific such as malaise, weight loss, left upper quadrant pain, and fever. Mortality rate is up to 47% in treated patients and can reach 100% among untreated patients. The timely and appropriate use of imaging methods viz, CT scan,

ultrasound and magnetic resonance imaging facilitates early diagnosis and guides treatment thus improving the outcome.

The initial approach in management depends on whether it is unilocular or multilocular. The former is amenable to CT or ultrasound guided drainage; and this approach, along with systemic antibiotic administration has a success rate of 75% to 90%. Surgery is reserved for patients who are stable and with multilocular abscesses. Splenectomy has long been considered the standard treatment of splenic abscess. Depending on available expertise, laparoscopic or open procedures can be considered. Post splenectomy complications include a mortality rate of 0-17% and a morbidity rate of 28-43%.

Percutaneous drainage has gained acceptance as an effective and less invasive treatment method than surgical intervention in selected patients e.g., unilocular or bilocular collections.<sup>4</sup> Multilocular abscesses, ill-defined cavities,

septations, and necrotic debris are contraindications for percutaneous drainage. Reported success rate of percutaneous drainage is 67-100%, as it preserves the spleen and avoids the risk of postsplenectomy complications. Percutaneous drainage can also be used as a bridge to elective surgery in patients who are clinically unstable or who have multiple comorbidities.<sup>5</sup>

---

## AUTHOR NOTE

---

V. Ravi Kumar, Assistant Professor of Surgery  
T R Chikkannachari, Professor of surgery  
Aparajitha Mukarji, Associate Professor of Surgery  
MVJ Medical College and Research Hospital,  
Hoskote, Bangalore.

Hareesh R S Kumar, Professor,  
Email: hareeshrashmi@gmail.com

### (Corresponding author)

Department of Forensic Medicine, Basaveshwara  
Medical College & Hospital, Chitradurga.

Rashmi Belodu, Assistant Professor  
Department of Microbiology, Basaveshwara  
Medical College & Hospital, Chitradurga.

---

## REFERENCES

1. Ng CY, Leong EC, Chng HC. Ten-year series of splenic abscesses in a general hospital in Singapore. *Ann Acad Med Singapore*. 2008;37(9):749-52.
2. Fotiadis C, Lavranos G, Patapis P, Karatzas G. Abscesses of the spleen: report of three cases. *World J Gastroenterol*. 2008;14(19):3088-91.
3. Alonso Cohen MA, Galera MJ, Ruiz M, Puig la Calle J Jr, Ruis X, Artigas V, et al. Splenic abscess. *World J Surg*. 1990;14: 513-517.
4. Westh H, Reines E, Skibsted L. Splenic abscesses: a review of 20 cases. *Scand J Infect Dis*. 1990;22(5):569-73.
5. Choudhury SR, Rajiv C, Pitamber S, Akshay S, Dharmendra S. Management of splenic abscess in children by percutaneous drainage. *J Pediatr Surg*. 2006;41(1):53-6.